

Brief Report

Rational Heart Transplant From a Hepatitis C Donor: New Antiviral Weapons Conquer the Trojan Horse

ROBERT L. GOTTLIEB, MD, PhD,^{1,2,3,4} TEENA SAM, PharmD,^{1,2,3} SUZANNE Y. WADA, MD,^{1,2,5} JAMES F. TROTTER, MD,^{1,2,6}
SUMEET K. ASRANI, MD,^{1,2,6} BRIAN LIMA, MD,^{1,2,3,7} SUSAN M. JOSEPH, MD,^{1,2,3,4}
GONZALO V. GONZALEZ-STAWINSKI, MD,^{1,2,3,7} AND SHELLEY A. HALL, MD^{1,2,3,4}

Dallas, Texas

ABSTRACT

Background: Donors with hepatitis C (HCV) viremia are rarely used for orthotopic heart transplantation (HT) owing to post-transplantation risks. New highly effective HCV antivirals may alter the landscape.

Methods: An adult patient unsuitable for bridging mechanical support therapy accepted a heart transplant offer from a donor with HCV viremia. On daily logarithmic rise in HCV viral load and adequate titers to ensure successful genotyping, once daily sofosbuvir (400 mg)–velpatasvir (100 mg) (Epclusa; Gilead) was initiated empirically pending HCV genotype (genotype 3a confirmed after initiation of therapy).

Results: We report the kinetics of acute hepatitis C viremia and therapeutic response to treatment with a new pangenotypic antiviral agent after donor-derived acute HCV infection transmitted incidentally with successful cardiac transplantation to an HCV-negative recipient. Prompt resolution of viremia was noted by the 1st week of a 12 week course of antiviral therapy. Sustained virologic remission continued beyond 12 weeks after completion of HCV therapy (SVR-12).

Conclusions: The availability of effective pangenotypic therapy for HCV may expand donor availability. The feasibility of early versus late treatment of HCV remains to be determined through formalized protocols. We hypothesize pharmacoeconomics to be the greatest limitation to widespread availability of this promising tool. (*J Cardiac Fail* 2017;23:765–767)

Key Words: Hepatitis C, pangenotypic, velpatasvir-sofosbuvir (Epclusa), orthotopic heart transplantation donor allocation.

From the ¹Baylor University Medical Center, Dallas, Texas; ²Baylor Annette C. and Harold C. Simmons Transplant Institute, Baylor University Medical Center, Dallas, Texas; ³Baylor Center for Advanced Heart and Lung Disease, Baylor University Medical Center, Dallas, Texas; ⁴Department of Internal Medicine, Texas A&M Health Science Center, Dallas, Texas; ⁵North Texas Infectious Disease Consultants, Dallas, Texas; ⁶Liver Consultants of Dallas, Dallas, Texas and ⁷Department of Cardiac and Thoracic Surgery, Baylor University Medical Center, Dallas, Texas.

Manuscript received May 29, 2017; revised manuscript received July 28, 2017; revised manuscript accepted August 1, 2017.

Reprint requests: Robert L. Gottlieb, MD, PhD, Baylor Center for Advanced Heart and Lung Disease, 3410 Worth Street, Suite 250, Dallas, TX 75246. Tel: (214) 820-6856; Fax: (214) 820-1474. E-mail: robert.gottlieb@bswhealth.org.

Funding: None beyond the acknowledgments.

See page 767 for disclosure information.

1071-9164/\$ - see front matter

© 2017 The Authors. Published by Elsevier Inc. This is an open access article under the CC BY-NC-ND license (<http://creativecommons.org/licenses/by-nc-nd/4.0/>).

<https://doi.org/10.1016/j.cardfail.2017.08.448>

Hearts from donors with hepatitis C virus (HCV) are underutilized for orthotopic heart transplantation (HT) owing to post-transplantation risks,¹ including increased recipient mortality and coronary allograft vasculopathy.^{2,3} New highly effective direct-acting antiviral agents (DAAs) that target multiple steps in the HCV replication life cycle⁴ could transform cardiac transplant outcomes after donor-derived HCV transmission.

Hepatitis C is an enveloped single-stranded RNA flavivirus of ≥6 viral genotypes with >50 subtypes. Until recently, effective treatment of HCV, even in the general population, required knowledge of viral genotype. Those treatment regimens with broader activity across genotypes required complex tailoring (eg, addition of ribavirin, with potential drug interactions), and activity against HCV genotype 3 remained a particular challenge. Although presence of HCV antibodies and viremia assessed with the use of nucleic-acid testing (NAT)

by means of polymerase chain reaction (PCR) are disclosed, genotype and viral titers are rarely available at the time of organ allocation given the time constraints. Transplanting a heart laden with an unknown genotype of HCV with the intention to deploy a DAA regimen to eradicate donor-derived HCV infection after transplantation would have been a daunting prospect until the advent of simpler therapies. Recently, an oral fixed-dose combination of sofosbuvir, a nucleotide-analogue NS5B inhibitor, and velpatasvir, an NS5A replication complex inhibitor, with pangenotypic activity against all 6 major HCV genotypes, became commercially available for chronic hepatitis C therapy.⁵

An HCV-seronegative adult female patient with biventricular heart failure was deteriorating clinically while awaiting a heart transplant at status 1A despite 2 inotropes, and was deemed to be unsuitable for bridging biventricular mechanical circulatory support. Owing to her acute state, a net survival benefit from cardiac transplantation was inferred, regardless of donor HCV status, based on historical data.² After discussion with the patient, her family, and multiple subspecialty providers, the restriction against hepatitis C viremic donors was removed. A suitable transplant was received from a young donor positive for both HCV antibody and NAT. The donor HCV genotype was unknown before transplantation, and the donor sample sent for post-transplantation genotyping was exhausted by other tests, necessitating viral genotyping from the recipient. The donor seroprofile demonstrated cleared wild-type hepatitis B infection (hepatitis B NAT negative, surface antibody positive, total core antibody positive, and surface antigen negative) and was HIV-1/2 negative according to both serology and NAT, and cytomegalovirus (CMV) IgG seropositive, resulting in a high-risk CMV mismatch for the CMV-seronegative recipient. Immunosuppression proceeded via standard institutional protocol with the use of basiliximab and

corticosteroid induction, tacrolimus, and azathioprine substituted for mycophenolate owing to the CMV mismatch. Valganciclovir (450 mg orally twice daily) and entecavir (0.5 mg daily) were prescribed prophylactically for the 1st 6 months because of the donor CMV and hepatitis B seroprofiles, respectively.

Hepatitis C viral RNA was undetectable through post-transplantation day 4, but on day 5 was detected below the limits of quantification. Logarithmic rise in HCV viral load ensued, with titers exceeding the threshold to ensure successful HCV viral genotyping from the recipient by day 13. Once-daily sofosbuvir (400 mg)–velpatasvir (100 mg) (Eplclusa; Gilead) was then initiated empirically pending HCV genotype. Viral titers fell promptly by post-transplantation day 14 and were consistently negative by post-transplantation day 23 (Fig. 1).

HCV genotype 3a was confirmed after initiation of HCV therapy. The patient received 12 weeks of sofosbuvir–velpatasvir therapy (last dose on post-transplantation day 96), and viral PCR remained negative after the subsequent 12 weeks, meeting the definition of sustained virologic response (SVR-12), the accepted end point in the hepatitis C literature. Creatinine, hepatic function test, and white cell count differentials were unremarkable on the conclusion of the anti-HCV DAA therapy. The patient did not experience any serious infection nor rejection episodes during the treatment period, and remained free of donor-specific antibodies and hospitalization with SVR one year following heart transplant.

Although the contemporary standard of care in cardiac transplantation has been to decline offers from HCV NAT-positive donors because of high risk of transmission to the recipient, in this particular clinical case a cardiac allograft from a hepatitis C viremic donor was transplanted based on the best-interest standard, without knowledge of the HCV

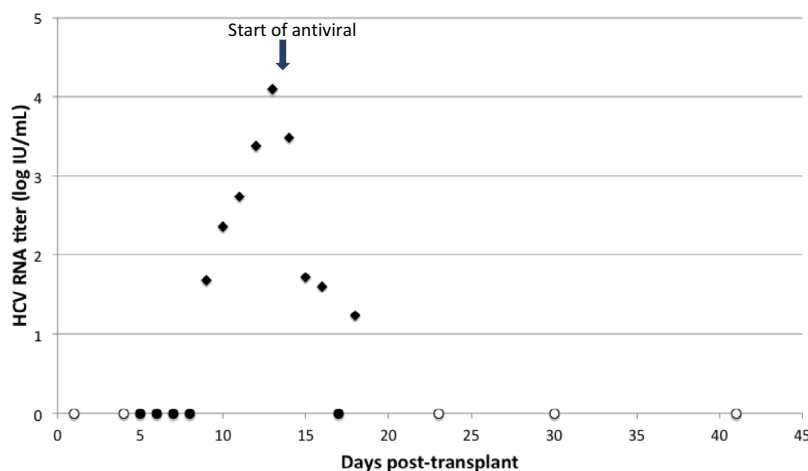


Fig. 1. Early post-transplantation viral kinetics and response to pangenotypic sofosbuvir–velpatasvir direct-acting anti-hepatitis C virus (HCV) therapy following cardiac donor-derived acute HCV genotype 3a transmission. Therapy was initiated on post-transplantation day 13.5 and continued through day 96. Day 0 = day of transplantation. Arrow indicates start of sofosbuvir (400 mg)–velpatasvir (100 mg) oral direct-acting antiviral therapy). Open circle = undetectable HCV titer (log 0 is undefined, placed at 0 on y-axis for clarity); solid circle = detectable viral titer but <15 IU/mL limit of quantification; diamond = quantifiable HCV titer. (Additional data not shown on graph are undetectable titers on post-transplantation days 52, 60, 67, 73, 81, 88, 104, 111, 117, 131, 139, 145, 153, 165, 173, 180, 188, 265, 299, 328, and 354).

genotype a priori and with a plan to institute a pangenotypic agent. In contrast, active trials exploring hepatitis C therapy to expand the use of renal transplant allografts from HCV-viremic donors require prior knowledge of HCV genotype. A prototypic trial limits donors to those infected with HCV genotype 1, given the restricted genotypic coverage of grazoprevir (100 mg)–elbasvir (50 mg) (Zepatier; Merck Pharmaceuticals).⁶

The use of a lung allograft from a hepatitis C–positive donor transplanted into a seronegative recipient has been reported.⁷ The HCV genotype was unknown until after transplantation, when it was determined to be genotype 1a, enabling the use of ledipasvir-sofosbuvir. However, whereas HCV genotype 3 is responsible for <10% of hepatitis C infections in the USA, it is more common in the donors becoming available as a consequence of the intravenous drug overdose epidemic. The availability of a well tolerated pangenotypic regimen was instrumental in ensuring eradication of the donor-derived HCV genotype 3a in our patient and is a requisite to enable optimal organ allocation if the safety of our strategy is confirmed on a larger scale.

The end-user cost of a 12-week course of direct antiviral therapy for hepatitis C is ~\$80,000–\$100,000. Additionally, FDA labeling for the DAA therapies include explicit approval for chronic HCV, without addressing acute HCV, leading most insurers to deny requests for treatment for acute post-transplantation hepatitis C infection. Transplant centers that might wish to apply this strategy on behalf of their patients are encouraged to investigate pharmacoeconomic constraints. Insurers may be encouraged to permit access to this HCV-positive donor pool to reduce the need for bridging mechanical support, which has its own attendant costs and risks.

Important management issues remain. Very early initiation of antiviral therapy may contribute to viral resistance if postoperative nausea or gastrointestinal complications limit the ability of the patient to tolerate oral therapy. The ideal regimen should be cost-effective and minimize side-effects and drug-drug interactions with coexisting immunosuppressants. Other donor or recipient factors add further complexity. In the present case, azathioprine was used rather than mycophenolate, because of the high-risk CMV mismatch, and it is unknown if this selection facilitated the efficacy of velpatasvir-sofosbuvir. Existing literature suggests that mycophenolate may have increased the risk of long-term adverse cardiac transplant outcomes after donor-derived HCV transmitted at the time of cardiac transplantation in the past.³ It is unknown whether mycophenolate complicates outcomes after donor-derived HCV treatment with the use of DAAs.

In conclusion, we have reported the kinetics of acute hepatitis C viremia and prompt therapeutic response to treatment

with the use of a new anti-HCV pangenotypic DAA after acute HCV genotype 3a infection transmitted knowingly with a cardiac transplant in an HCV-seronegative recipient. The pangenotypic sofosbuvir-velpatasvir anti-HCV regimen facilitated the successful allocation of an organ that would likely have been discarded otherwise. The hepatitis C virions that entered the transplant recipient with the transplanted heart were conquered and the organ redeemed.

Disclosures

Dr James F. Trotter has received professional research grants and has served on the speakers bureau for Gilead Pharmaceuticals.

Acknowledgments

The authors extend their gratitude to the patient described in this paper for her courageous inspiration as she refused to allow lack of a conventional organ donor to affect her *joie de vivre*. They acknowledge the Baylor Transplant Patient Assistance Fund which helped to provide bridging outpatient pharmaceutical supply while awaiting the insurance appeals process for obtaining the DAA. They also thank Charlene Cink and Kirk Starr for their patient advocacy. Dr Gottlieb acknowledges Dr Frances Johnson for early career mentorship.

References

1. Kim E, Ko HH, Yoshida EM. A concise review of hepatitis C in heart and lung transplantation. *Can J Gastroenterol* 2011;25:445–8.
2. Haji SA, Starling RC, Avery RK, Mawhorter S, Tuzcu EM, Schoenhagen P, et al. Donor hepatitis C seropositivity is an independent risk factor for the development of accelerated coronary vasculopathy and predicts outcome after cardiac transplantation. *J Heart Lung Transplant* 2004;23:277–83.
3. Gasink LB, Blumberg EA, Localio AR, Desai SS, Israni AK, Lautenbach E. Hepatitis C virus seropositivity in organ donors and survival in heart transplant recipients. *JAMA* 2006;296:1843–50.
4. Asselah T, Boyer N, Saadoun D, Martinot-Peignoux M, Marcellin P. Direct-acting antivirals for the treatment of hepatitis C virus infection: optimizing current IFN-free treatment and future perspectives. *Liver Int* 2016;36:47–57.
5. Lee R, Kottitil S, Wilson W. Sofosbuvir/velpatasvir: a pangenotypic drug to simplify HCV therapy. *Hepatol Int* 2017;11:161–70.
6. Goldberg D, Reese P. Zepatier for Treatment of Hepatitis C–Negative Patients Who Receive Kidney Transplants From Hepatitis C–Positive Donors (HCV). *ClinicalTrials.gov Identifier: NCT02743897*.
7. Khan B, Singer LG, Chaparro C, Martinu T, Juvet S, Pipkin M, et al. Successful lung transplantation from hepatitis C positive donor to seronegative recipient. *Am J Transplant* 2017;17:1129–31.